

Transformation for learning and learning to transform!

by Dr. Nikos Mattheos



Being myself not a fan of action blockbusters, I was always dismissive to the "Transformers" series, with possibly the only exception being the Age of Extinction (2014) which was filmed in Hong Kong and included scenes of giant robots marching down from the Peak, some spectacular fights in Yik Cheong Building and flying HK red cabbies. I found the idea of human-form robots that transform into super cars, airplanes or trucks quite absurd. Looking back to our lives in the past 6 months, I can only wish we too had a similar ability for transformation!

The amount of disruption we have all experienced in our lives and practice of dentistry is unprecedented in living memory. There is no doubt we have entered a period of transformation, albeit nobody appears to know what our lives are being transformed into. On the other hand, this is the time when learning can make the difference. Learning as a crucial survival skill. Learning lies in the heart of every change, as learning in itself is a major process of transformation, moving from one state of mind to another. Increasing your skillsets and competences is only worth when it makes you able to see more, decide more efficiently and act more effectively.

In the past 6 months, the disruption in conventional education made it painfully obvious to us all that we have to learn "how to learn" in new ways. With major congresses being cancelled one after the other, courses and universities shutting down all over the world, online platforms moved in to fill the void. As always, the start was somewhat rushed and unstructured and an endless series of webinars does not necessarily equal to quality and meaningful education. Even with the virus defeated however, the disruption is here to stay and it might take long till the world slowly gravitates to a new normal.

"Resilience is great, Adaptation is better, but Innovation is the key!"

At CDE, we took up the challenge of transformation to a new model, where on-line learning will be strategically employed in structured learning pathways, established global experts will foster local talent and innovative 3D technologies will bring the hands-on experience irrespective of time and place. It will be a marathon rather than sprint, but we have already started and in the coming months you will see many elements of new learning strategies unveiled.

September will start with the premiere of a novel concept, an education cycle organised by Dr. James Chow, world class OMF Surgeon and Digital Dentistry visionary. The cycle will blend online and face-to-face with modules building competencies gradually to a complete hands-on experience through innovative 3D printing technology. Then October and November follow suit with many new topics and speakers as well as the re-launch of many successful courses of the past year, including our unique implant residency, with supervised clinical practice.

As 2020 moves into its final chapter, we take the challenge to transform. Let's transform together..!



Editorial

- Interview with Dr. James Chow
- Smiling with Confidence
- Comprehensive Oral Rehabilitation
- ITI Campus HK News
- CDE Upcoming Courses



in this Issue



"Lockdown" was a ruthless, cold hearted and barbaric Lamborghini Aventador robot in the HK-filmed Age of Extinction. In the end, Optimus Prime kills "Lockdown" and although Hong Kong gets a bit messy in the process, we all live happily ever after!

ITI Campus Hong Kong: A regional hub for a global network!

ITI is the largest global association of professionals in implant dentistry and this year is celebrating 40 years of service! ITI aims to promote the evidence-based practice of implant dentistry through education, research and exchange of knowledge. With more than 20,000 Fellows and Members worldwide, and active sections in almost every country, ITI ensures the global exchange of expertise and know-how via a modern and efficient network, while developing and promoting the next generation of leaders in implant dentistry at the local, national and international level.

ITI benefits its members with cutting edge education combining on-line with face-to-face through the ITI Online Academy, the ITI Curriculum, ITI Study Clubs, the ITI Net, ITI Treatment Guides and more. Furthermore, ITI provides education scholarships, and

major grants promoting groundbreaking research and supporting publication and dissemination of the results. Large workshops are conducted every 3 years for the production of new practice guidelines. By proactively defining relevant areas of investigation and identifying gaps in current knowledge, it

The recently established ITI Campus HK is a regional hub of implant dentistry enthusiasts, aspiring to connect local

practitioners with world class education and cutting edge practice! Supported by world class specialists, academics and practitioners, all committed ITI fellows and members, the HK Campus aims in promoting the evidence-based practice of implant dentistry through organising quality education, mentoring and networking. The Campus is a regional gateway to all-things-ITI and offers the ITI Curriculum, ITI Study Clubs as well as other opportunities for growth in the modern practice of Implant Dentistry! Whether you are a colleague making your first steps or a seasoned expert, the ITI Campus HK is the place to share and grow your passion for Implant Dentistry! Stay tuned for the upcoming events and opportunities!

If you want to find out more about the ITI Campus Hong Kong and how it could help you expand your practice of implant dentistry, please contact us at +852 2105 1000.



Comprehensive Oral Rehabilitation: The Multidisciplinary Way to a Healthy Smile!

by Dr. Jerry Liu



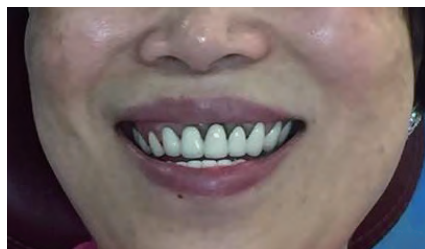
Case

Restoring aesthetics and function, is never a matter of a quick-fix. On the contrary, a detailed in-depth analysis of all visible and invisible influences is a prerequisite for staging a successful multidisciplinary rehabilitation. Dr. Liu shares with us all steps in complex oral rehabilitation case that stretches over a period of almost 2 years, combining health, function and aesthetics in fulfilment of the patients needs.



Examination

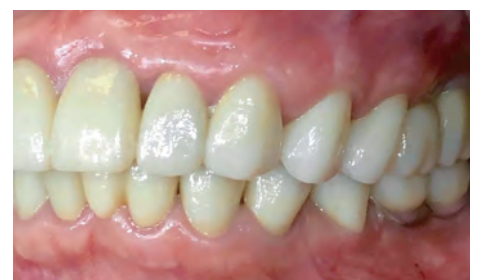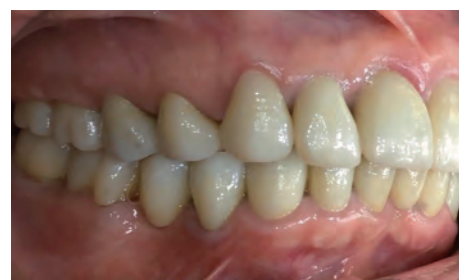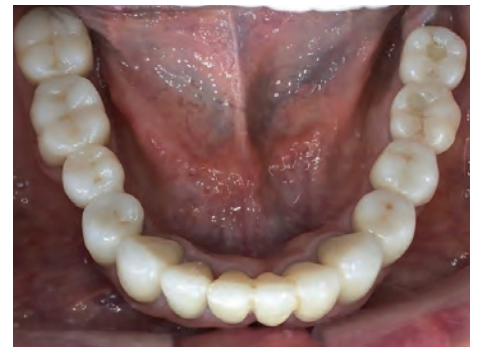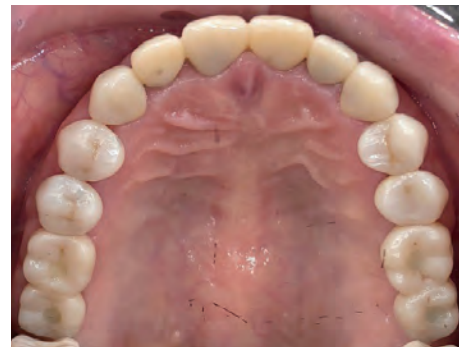A 68 year's old female, sought advise on her dental problems in September 2017. She was complaining of 1) poor dark margin on her upper anterior teeth, 2) poor chewing efficiency, 3) chewing muscle tiredness and occasional pain after eating. The history showed that the complaints of poor chewing efficiency and muscle problems occurred after the placement of upper and lower crowns and bridges, approximately 8 years earlier. The dark crown margins on upper anterior crown were noticeable when the already when the prosthesis was delivered, but the condition had deteriorated in the recent years.



The medical history of the patient was clear. She was not a smoker and she did not drink alcoholic beverages. The dental history was investigated for potential reasons of the extensive crown and bridgework. Patient had received multiple endodontic treatments and crowns for aesthetic reason about 30 years earlier. The last treatment involved replacing all existing crowns as well as the missing molars 16, 17, 26, 27 and 36, which were extracted due to caries under the crown or bridge abutment.

A complete extra-oral examination showed that the masticatory muscles and sternocleidomastoid muscles were tender to palpation. Maximum mouth opening was 43mm, within the normal range. Bilateral joint clicking in late opening and early closing moment was observed. Jaw deviated to the right in opening movement. Lateral joint movement to the left was limited to 7mm while movement to the right was 9mm. No inflammatory response was suspected in both joints and there was no pain at joint loading test. No other abnormalities in extra-oral hard and soft tissue were detected.

The intra-oral examination revealed generalised gingivitis. The crown margins of 12, 13, 14 were subgingival and encroached the biologic width. Teeth 15 to 25 were restored



with joint crowns with cantilever pontics on 16, 17 and 26, 27. Sinus tract opening was detected at the apical area of 21. Teeth 33 to 43 were restored with a bridge with 31 pontic. Teeth 44 to 47 were restored with single crowns. Gross root caries was detected at 45D. Teeth 34 to 37 were restored with a bridge with 36 pontic. The crown on tooth 37 was decemented, and gross secondary caries was detected. All crowns and bridges were made as ceramic bonded to metal type.

Radiographic examination with cone-beam CT showed that multiple teeth were root canal treated and restored with cemented type metal post, including 13, 12, 11, 21, 22, 23, 35, 34, 33, 32, 41, 42, 43, 44, 45. Most of the root fillings appeared shorter than the ideal anticipated length. Teeth 12, 21, 41, 44 were associated with periapical radiolucencies. All 4 teeth were tender to percussion.

Diagnosis

The diagnoses of the patient were as follows:

1. Generalised gingivitis.
2. Caries 37, 45
3. Biologic width violated by deep subgingival crown margin 12, 13, 14.
4. Apical periodontitis 12, 21, 41 and 44.
5. Unfavourable biomechanical condition due to short post 13, 12, 11, 21, 22, 23, 35, 34, 33, 32, 41, 42, 43, 44, 45.



Insights is the Newsletter of the Center of Dental Education (CDE), promoting quality dental education in Hong Kong and the region. Opinions and views expressed in this Newsletter reflect the views of the respective authors and not necessarily of CDE.



About Us

Editor: Dr. Nikos Mattheos
Editorial Team: Ashley Wong, Ivy Yip, Jameson Wu, Romain Leung, Terence Wong
Graphic Design: Desmond Lam
Email: info@cde.hk
Tel: +852 8481 1770
Address: 17/F, CEO Tower, 77 Wing Hong Street, Cheung Sha Wan, Kowloon



6. Aesthetic failure due to metal crown margin 12, 11, 21, 22, 23.
7. Asymmetric gingival height 13 to 23.
8. Unfavourable mechanic conditions with cantilever pontic 16, 17, 26, 27 in the upper bridge.
9. Occlusal Dysfunction with associated muscle pain (tentative).

The tentative treatment plan involved crown lengthening procedures, revision of root canal treatments and post and core reconstructions, full mouth rehabilitation by means of single full ceramic crowns, 3-unit bridges 32 to 41 and implant replacement of missing molars. Pros and cons of treatment plan were discussed and explained. Consent for proceeding on the basis of the tentative treatment plan was obtained. Patient understood that final treatment plan could only be made after confirming the diagnosis of the occlusal dysfunction, as well as the prognosis of 37 and 45.

A final treatment plan was made after examining 35 and 37. Both teeth were fractured to the extent of being unrestorable and therefore extracted. Tooth 37 was planned to be replaced by implant. Tooth 35 was to be replaced by a 3 units bridge, as the patient did not wish to receive a bone graft. Deep caries was found under the crown 15 and root canal treatment was decided. Occlusal Dysfunction was confirmed by using Kois Deprogrammer. Patient was asked to wear the appliance for 2 weeks. Bite at centric relation (CR) was taken after confirming the masticatory muscles were fully deprogrammed.

Treatment Plan

The final treatment plan was confirmed as follows:

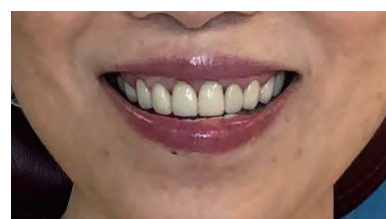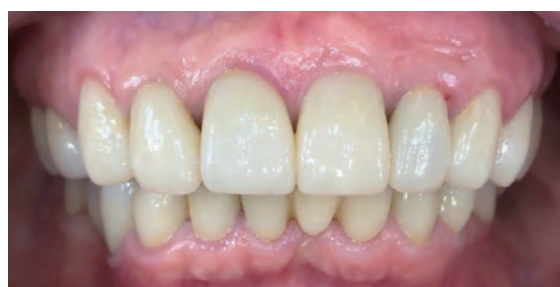1. Scaling and oral hygiene instruction.
2. Replacement of all existing crowns and bridges with PMMA temporary crowns and PMMA bridges for missing teeth 31 and 45.
3. Adjustment of the occlusion of the temporary crowns and bridges, so as to establish the MIP in CR, VD to remain unchanged.
4. Revision of root canal treatments 12, 21, 41, 44.
5. Replacement of defective post and core reconstructions 13, 12, 11, 21, 22, 23, 35, 34, 33, 32, 41, 42, 43, 44 with metal post and composite core.
6. Root canal treatment 15, metal post and composite core.
7. Crown lengthening procedures 13-23 with connective tissue graft on recipient site 11-23.
8. Implant replacement 16, 17, 26, 27, 36, 37.
9. Monolithic Zirconia full anatomical crowns on natural teeth and implant 17 to 27, 37 to 33, 42, 43 and 47.
10. Monolithic Zirconia full anatomical bridges 32 to 41, 44 to 46.

Temporization phase

The upper PMMA temporary crowns were made according to the design of upper anterior crown height and the general horizontal of the patient's upper occlusal plane. The lower temporary crowns and bridges were made with ideal occlusion with the upper arch in CR position. The vertical dimension remained unchanged. The spaces of 16, 17, 26, 27, 36, 37 were left edentulous during temporization phase. All temporary crowns and bridges were cemented with Tempbond. Several appointment were made for occlusal refinement until the patient felt fully comfortable with the bite and the subjectively reported chewing efficiency was restored to normal.

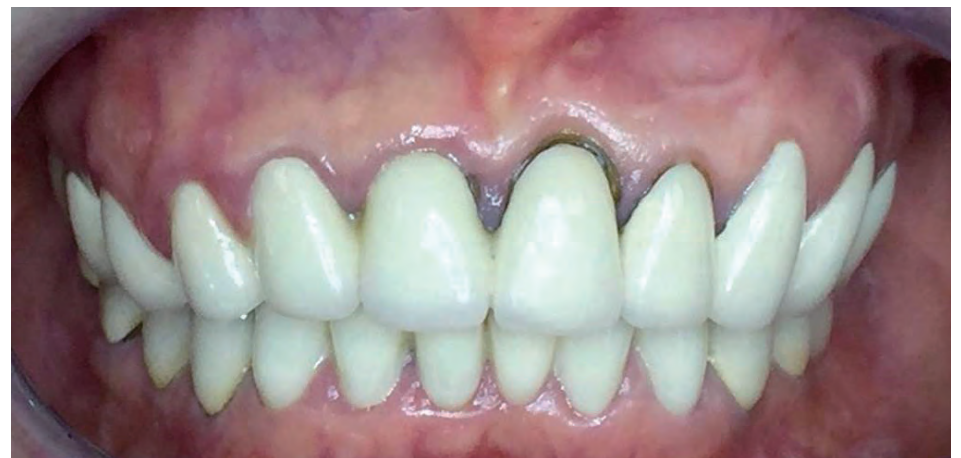Endodontic treatment, Periodontal surgery and Implants

Patient was then sent to endodontist for revision of root canal treatments. The crown lengthening procedure was completed by a periodontist and a healing period of 6 months was allowed for the soft tissue outcomes to mature. Implants at 16, 17, 26, 27, 36, 37 were installed during this period and screw retained monolithic zirconia final crowns were delivered. Special attention was paid on occlusal adjustment, so as to comply with the existing MIP supported by temporary crowns and bridges. The centric occlusion was maintained in CR during this phase. Symmetric gingival height 13 to 23 was achieved 6 months after the surgery.



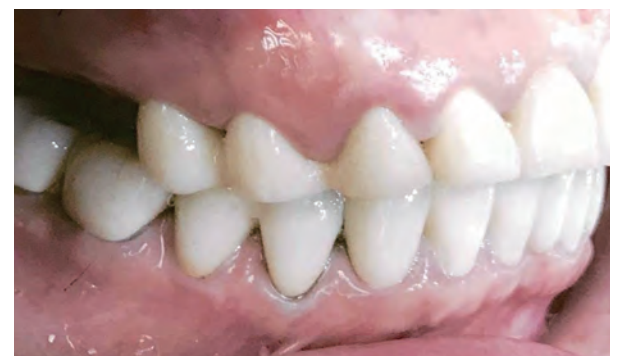
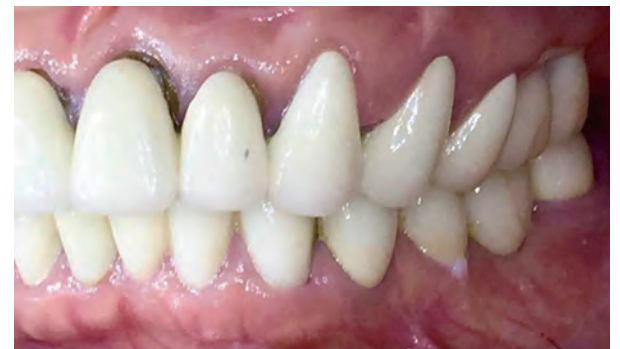Final Reconstruction

As the existing short posts were to be replaced by stainless steel parallel ones, teeth 13, 32, 43 required root canal retreatment because the existing root filling material was not good enough to support new post length. After all root canal

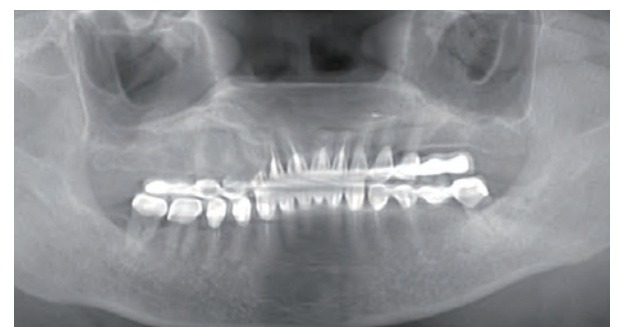

fillings were ready, the stainless steel parallel posts were cemented with RelyX Unicem2 and All Bond Universal bonding agent. Composite cores were built with Nano filled composite 3M Z350 and All Bond Universal bonding agent. Tooth preparations were refined. Impressions for full arch working models were taken by polysiloxane under double cord technique. The final crowns were made according to the desired upper anterior crown height and patient's general horizontal plane. Bite was taken at CR and VD remained unchanged. The final restorations were finished with monolithic Zirconia crowns and bridges in one visit.

All Zirconia restorations were decontaminated by air-abrasion with 27 microns Aluminum oxide particles at 40psi to remove any salivary or blood contaminants. Zirconia was primed with MDP for one minute. The crowns and bridges were cemented with automix RelyX Unicem2, after the teeth were decontaminated by air-abrasion with the same setting mentioned above, under good moisture control. The cement was light cured and excessive cement was carefully removed. Occlusal adjustment, with the help of lift gauge, was carried out to settle the MIP of the final restorations in CR. All crowns and bridges were carefully polished until glazing surface appeared.



The patient was satisfied with the treatment outcome. The aesthetic appearance of Zirconia crowns and bridges, in terms of translucency and margin integrity, met the patient's expectation. The self-adhesive resin cement 3M RelyX Uniem2 provides high elastic modulus and strong marginal seal for the best possible longevity of cement in function. The symmetric gingival level 13 to 23, allowed symmetric crown appearance in the aesthetic zone. The occlusal plane, which followed patient's general horizontal, provided a balance and levelled plane for patient's smile. The chewing function of dentition was restored into high proficiency, according to the patient's subjective report. The masticatory and neck muscles were not tender to palpation after the MIP was settled in CR by temporary crowns and bridges. This occlusal scheme became the surrogate result of her final restorations. The muscles were maintained in healthy status during the first year review.



The case was completed in April 2019. One year post-op review showed small fragment of cement remnants causing gingivitis at 11M and 22D, which were removed accordingly. Overall healthy gingiva, nice margin integrity, beautiful bright smile and excellent chewing function were maintained.

Do you want to learn more about the strategies and techniques involved in this case? Don't miss the in-depth course of Dr. Jerry Liu on 11/12 & 18/12.

<https://www.cde.hk/courses/80#content>



Dr. James Chow has earned his reputation in many fields: an excellent OMF Surgeon, a world-class speaker, a teacher, a successful entrepreneur, a pioneer in digital dentistry and digital education. In a time when more and more colleagues are “converting” to a digital workflow, Dr. Chow is already envisioning the next step! We got some time of his busy schedule to discuss some of his latest plans and activities and get a glimpse of what lies ahead in the practice and teaching of dentistry!

• You have been an early champion of the digital workflow in implant dentistry. Is your implant practice workflow fully digital today?

We have entered the Dental Digital Age since 2003 by using dental implant planning software and 3D printing. Throughout the years, we’ve gradually brought in different digital gadgets one by one and slowly but persistently integrated these various technologies into our daily clinical and laboratory practice. Today, although we can call ourselves highly digital, we are still working towards a complete digital workflow for implant dentistry.

• What are the major advantages you have seen with the digital workflow in implant surgery today as a clinician?

Above all, the digital workflow makes the treatment more predictable and allows us to be more creative when it comes to problem solving. Certainly, there are other advantages. It is minimally invasive, it is less affected by the clinical experience of the operators, and it facilitates immediacy.

• Is the Digital Workflow beneficial also from a business / practice management point of view?

It is adding value and it helps differentiate the practice from competitors; it leads to more predictable treatment outcomes and hence it builds reputation and enhances the word of mouth business strategy.

• How would you advice colleagues to start with the digital workflow? Which are the most common barriers or obstacles a colleague will follow when trying to adopt a digital workflow in implant dentistry?

The digital transformation is a long and winding process and it still remains a substantial investment to establish a complete digital workflow in clinical practice. The learning curve is steep, and it is a team approach; once committed, colleagues should take their time to do it step by step. Be persistent and be patient!



Interview

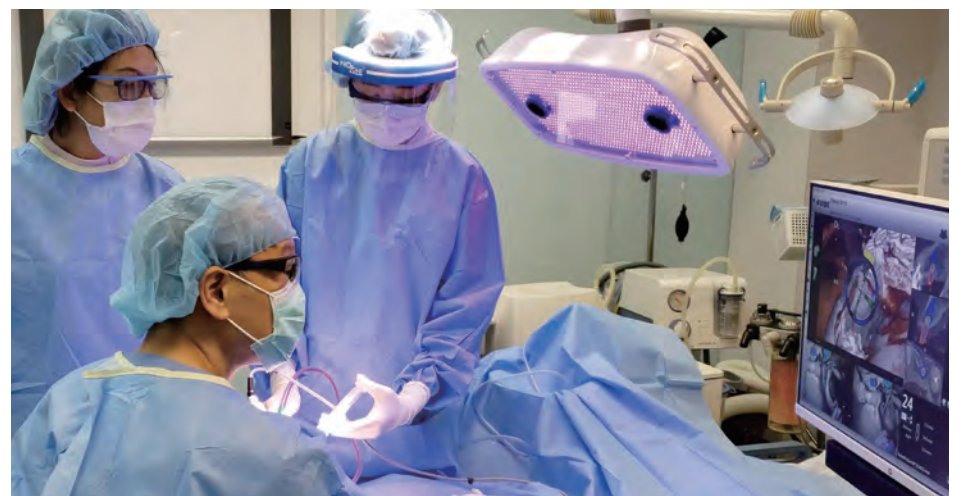

• Apart from mastering technology for your practice, I know you are also into pioneering technology for education! You have recently started a company researching in virtual surgery simulations and 3D printing. How do you see the role of such technologies in the way we practice and learn in the near future?

Definitely digital training is the future. And the future is near! In fact, we have already seen the use of digital simulators in the undergraduate program in some universities. Dentistry depends heavily on the manual skills of the operators. It is a global trend to witness a shortage of teaching cases for undergraduates and postgraduates and life-like simulation whether it is a 3D printed model, or a virtual reality program will become more and more important for students and practitioners to learn their skills.

• Finally, you have recently edited a textbook on Zygoma implants! What do you think is the future of Zygoma implants? Do you see their role to continue in the future or do you foresee changes?

Zygomatic implant is a predictable treatment in the management of severely atrophic maxilla. It is also well-documented. A recent randomised study comparing Zygomatic implants to major sinus lift grafting revealed that Zygomatic implants have many advantages over the grafting procedure. Through the optimisation of hardware and software of the Zygomatic implant, it is becoming the mainstream of treatment in implant reconstruction of edentulous maxilla worldwide.



Dr. Chow operating with real-time navigation, technology that allows the surgeon to “see” with mm precision the position of surgical instruments on the actual anatomy.

Do you want to find out more? Don't miss the opportunity to learn from Dr. Chow's curated series of webinars on Digital Workflow in Dentistry this September at CDE!

Furthermore, master the art and science of wisdom teeth surgery with the help of tailor made models and education material at Center of Dental Education.

<https://www.cde.hk/courses/98#content>



Smiling with confidence: Is a “Gummy smile” something to worry about?

by Dr. Jack Ji

Smiling with confidence is not a privilege, but something that everyone should enjoy, as smiling is an essential and powerful social function. When people feel they have to hide their mouth when they smile or laugh, they might be unhappy with the condition of their teeth. It could be due to crooked teeth, dark teeth, or even bad breath. But even with perfect teeth, an increasingly more common reason to make people uncomfortable with their smile is the “gummy smile”. A gummy smile shows too much gum tissue during smiling, which is also known as excessive gingival display (Armitage 1999). Showing 4mm or more gingivae during emotional smile is regarded as “gummy” and has been perceived as “unattractive” by both lay people and dentists. (Kokich 1999)



Clinical Theme



Several physiological or pathological conditions can result in excessive gingival display (Robins 2016).

- Vertical maxillary excess or orthognathic problems
- Short or “incompetent” upper lip
- Hyperactive upper lip
- Dentoalveolar extrusion
- Altered passive eruption
- A combination of the above factors

Whether a “gummy smile” requires correction depends not only on the aetiology, but also on patients’ needs and perception of facial aesthetics. Consequently, several treatment modalities are available based on the aetiological factors which contribute to the excessive gingival display. Based on the above indications, most common interventions would include:

Orthodontic / Orthognathic treatment:

Vertical maxillary excess is usually presented with long lower third of the face, lip incompetence and excessive incisal display without incisal wear. Mild vertical maxillary excess can be managed orthodontically, while moderate to severe maxillary excess should seek orthognathic consultation with oral maxillofacial surgeons.

Short or hyperactive upper lip:

The normal length of upper lip ranges from 20 to 24mm, and the normal upper lip mobility ranges from 6-8mm. Treatment options for short upper lip and hypermobile upper lip include lip repositioning surgery and Botox treatment.

Dentoalveolar extrusion:

Dentoalveolar extrusion is usually associated with tooth wear of upper and/or lower dentitions, which is clinically presented as short clinical crowns. The underlying causes of dentoalveolar extrusion should be determined, and the treatment usually engages multiple specialties, including prosthodontics, periodontics and orthodontics.

Altered passive eruption:

Altered passive eruption occurs as a result of failure of apical migration of gingival margin and/or alveolar crest (Goldman 1968). "Short and square teeth" are common complaints from patients, yet altered passive eruption is easily missed by many dental practitioners. Patients with altered passive eruption are usually presented with short clinical crowns, thick gingival phenotype and undetectable cemento-enamel junction (CEJ) from the gingival sulcus. Radiographic examination and/or clinical bone sounding are important to detect where the bone level is in relation to CEJ. Classification of altered passive eruption is based on the bone level and the amount of keratinized gingivae (Coslet 1977). Altered passive eruption can be managed with periodontal surgery, including gingivectomy, apical reposition flap,

and crown lengthening with bone reduction. If the bone is 2mm away from CEJ, which is at its normal position, gingivectomy can be used with either scalpel or laser if the keratinized gingivae is sufficient. Otherwise apical reposition flap should be adopted to preserve the keratinized gingivae around teeth. If the bone level is close to or at the level of CEJ, gingivectomy alone will not address the problem, as the re-establishment of biologic width above the bone crest will cause rebound of the gingivae (Gargiulo 1961). Crown lengthening procedure with full thickness flap, osteoplasty and ostectomy is the appropriate treatment to achieve long-term stable outcome.

With multifactorial aetiologies and different treatment approaches, gummy smile is one of the most frequent reasons for patients to seek aesthetic improvement in dental practice. Careful clinical evaluation, assessing the anatomy, the functional movements and oro-facial aesthetics, will help clinicians to identify the underlying causes and define the patients' needs. Thereafter, the appropriate treatment will be devised, which will often involve practitioners of different specialties. The final outcome should be a healthy and confident smile for the patient.

Ji Chao
BDS, MS, Cert. in Perio.
Diplomate, American Board of Periodontology

Do you want to learn more about how to diagnose the underlying conditions of a gummy smile and the treatment options available? Don't miss Dr. Chao's seminar on 14/10, 28/10 & 11/11.

<https://www.cde.hk/courses/100#content>



Reference

1. Armitage, G.C., 1999. Development of a classification system for periodontal diseases and conditions. *Annals of periodontology*, 4(1), pp.1-6.
2. Kokich Jr, V.O., Asuman Kiyak, H. and Shapiro, P.A., 1999. Comparing the perception of dentists and lay people to altered dental esthetics. *Journal of Esthetic and Restorative Dentistry*, 11(6), pp.311-324.
3. William Robins, 2016. *Global Diagnosis: A New Vision of Dental Diagnosis and Treatment Planning*
4. Goldman HM, Cohen DW. *Periodontal therapy*. 4th ed. St. Louis: Mosby; 1968.
5. Coslet, J.G., Vanarsdall, R. and Weisgold, A., 1977. Diagnosis and classification of delayed passive eruption of the dentogingival junction in the adult. *The Alpha Omegan*, 70(3), p.24.
6. Gargiulo, A.W., Wentz, F.M. and Orban, B., 1961. Dimensions and relations of the dentogingival junction in humans. *The Journal of Periodontology*, 32(3), pp.261-267.

CASE Report

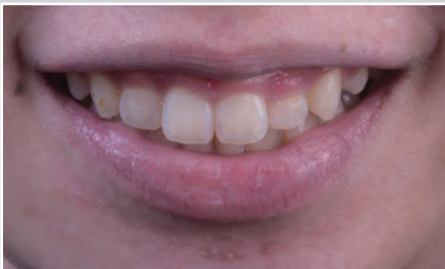A 26-year-old Asian lady complains of her gummy smile and requests smile aesthetic improvement prior to her wedding photo shooting in two months. She shows around 4mm gingivae around maxillary central incisors and 6mm gingivae around lateral incisors when she smiles. She is presented with normal mid-to-lower facial proportion, and the upper lip length and mobility were within normal range. Clinical evaluation revealed short clinical crowns of maxillary incisors, canines and premolars. There was no tooth wear identified. The length to height proportion of maxillary central incisors was around 100%. CEJs were not detectable from the gingival sulcus, and radiographs showed that the bone levels were close to CEJ of maxillary teeth. The excessive gingival display in her case is diagnosed to be attributed to altered passive eruption. Aberrant maxillary labial frenum was noticed as well. The treatment plan included esthetic crown lengthening for teeth 15 to 25, and frenectomy of labial frenum.



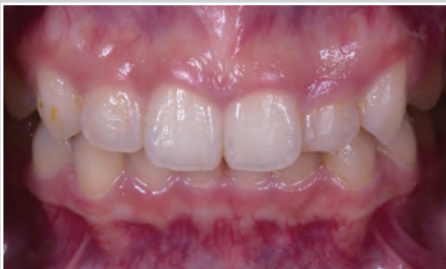Case



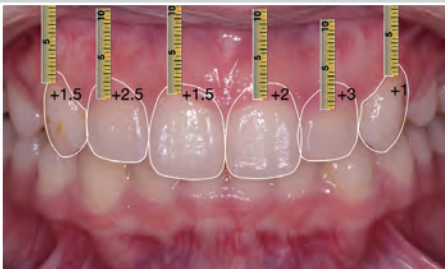
A comparison of her smile before and after the esthetic crown lengthening surgery. She smiles naturally and beautifully in her wedding photo.



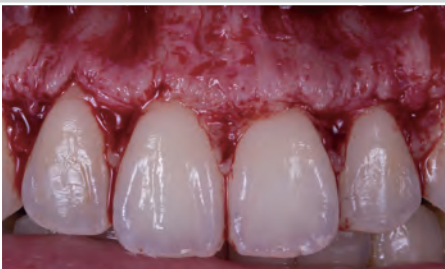1. Patient complains of "gummy smile"



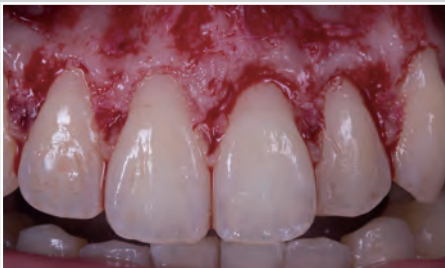2. Intraoral presentation of short clinical crowns



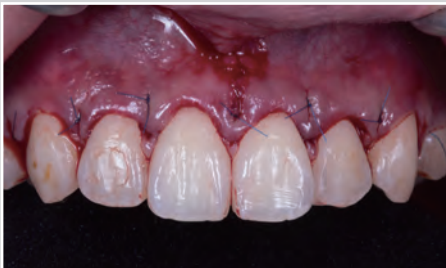3. Crowns with ideal proportion and the numbers indicate the amount of tooth structure in millimeters to be exposed



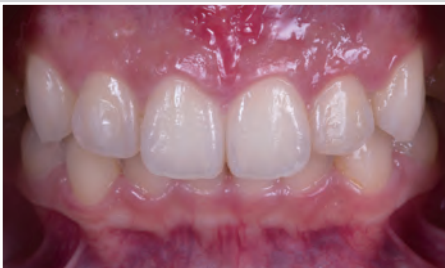4. Full thickness buccal flap was raised confirming the bone level to be too close to the CEJ. Altered passive eruption is confirmed. Interdental papilla tissue was preserved through split thickness incision.



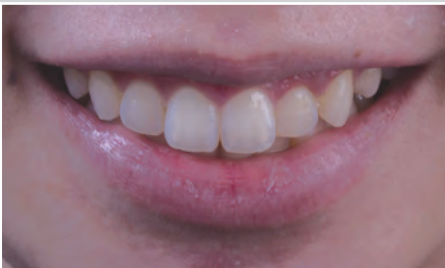5. An aesthetic crown lengthening procedure was performed, including osteoplasty and ostectomy.



6. Immediate postoperative photo after crown lengthening and frenectomy



7. Two-week postoperative photo after suture removal










8. Patient shows minimal amount of gingivae during emotional smile after aesthetic crown lengthening.









Courses Calendar


September

- 7 Mon  **Digital Dentistry Webinar 1 - Digital Technology for Immediate Function – An Overview**
Dr. James Chow
- 10 Thu  **Digital Dentistry Webinar 2 - Digital Technology for The Management of M3**
Dr. James Chow
- 14 Mon  **Digital Dentistry Webinar 3 - "Intra-oral Scanning. How can it benefit me in my practice?"**
Dr. Bruce Lee
- 17 Thu  **Digital Dentistry Webinar 4 - Digital Photography for Aesthetic**
Mr. Benny Au Yeung
- 21 Mon  **Digital Dentistry Webinar 5 - Digital Workflow and Optimisation in Guided Implant Surgery**
Dr. Raymond Chow
- 24 Thu  **Digital Dentistry Webinar 6 - The impact of digital technology and innovation in clinical dentistry**
Dr. Wong Keng Mun
- 28 Mon  **Implement concepts of Periodontics for Predictable Outcomes in Clinical Practice**
Dr. Ho Kam Yuen Simon




October

- 7 Wed  **Module 1 - Straumann Implant family – quarter century of history and experiences**
Dr. Gerald Siu
- 9 Fri  **Endo-Periodontal Lesions – Diagnosis, Prognosis & Management**
Dr. Liu Hin Nam
- 14 Wed  **Immediate Implant Placement - Why and How?**
Dr. Ji Chao, Jack
- 16 Fri  **Deciphering the periodontally involved molars – prognosis, management, and implications of their long-term retention and loss**
Dr. Fok Melissa Rachel
- 21 Wed  **Module 2 - Bone grafting procedures in GDP**
Dr. Gerald Siu
- 28 Wed  **Coverage of Exposed Root Surface in a Biologically Oriented Approach**
Dr. Ji Chao, Jack

November

- 4 Wed  **Module 3 - Sinus lift surgery made possible in GDP**
Dr. Gerald Siu
- 7 Sat  **Implant mini Residency 1**
Dr. Nikos Mattheos
- 11 Wed  **Diagnosis and Treatment of Gummy Smile from A Periodontal Aspect**
Dr. Ji Chao, Jack
- 14 Sat  **Implant mini Residency 2**
Dr. Nikos Mattheos
- 18 Wed  **Key Concepts & Practical Tips on Periodontal Regeneration and Mucogingival Surgeries**
Dr. Anita Chan
- 22 Sun  **Day 1 - Harnessing the Power of Digital Technology to Improve M3 Management**
Dr. James Chow
- 23 Mon  **Day 2 - Harnessing the Power of Digital Technology to Improve M3 Management**
Dr. James Chow
- 28 Sat  **Implant mini Residency 3**
Dr. Nikos Mattheos
- 29 Sun  **Day 1 - Computer Guided Implant Surgery for Management of Single to Full Edentulous Rehabilitation**
Dr. Raymond Chow
- 30 Mon  **Day 2 - Computer Guided Implant Surgery for Management of Single to Full Edentulous Rehabilitation**
Dr. Raymond Chow

December

- 5 Sat  **Implant Mini Residency 4**
Dr. Nikos Mattheos
- 11 Fri  **Perfecting Crown & Bridge Protocol for the Daily Practice: a Magic Play under Kois' Perspectives**
Dr. Liu Kwong Shing, Jerry
- 18 Fri  **Perfecting Crown & Bridge Protocol for the Daily Practice: a Magic Play under Kois' Perspectives**
Dr. Liu Kwong Shing, Jerry